



# Microcirculatory assessment of vascular diseases

Antonella Marcoccia<sup>1,8</sup>, Peter F. Klein-Weigel<sup>2,8</sup>, Michael E. Gschwandtner<sup>3,8</sup>, Jean-Claude Wautrecht<sup>4,8</sup>, Jiri Matuska<sup>5,8</sup>, Ulrich Rother<sup>6</sup>, and Alfons J. H. M. Houben<sup>7,8</sup>

<sup>1</sup> Unità di Medicina Vascolare e Autoimmunità, CRIIS-Centro di riferimento interdisciplinare per la Sclerosi Sistemica, Rome, Italy

<sup>2</sup> Klinik für Angiologie, Zentrum für Innere Medizin II, Ernst von Bergmann Klinikum, Potsdam, Germany

<sup>3</sup> Medizinische Universität Wien, Universitätsklinik für Innere Medizin II, Klinische Abteilung für Angiologie, Vienna, Austria

<sup>4</sup> Service de Pathologie Vasculaire, Hôpital ERASME, Université Libre de Bruxelles, Brussels, Belgium

<sup>5</sup> MATMED s.r.o., Private Angiology Facility, Hodonin, Czech Republic

<sup>6</sup> Gefäßchirurgische Abteilung, Universitätsklinikum Erlangen, Friedrich-Alexander-Universität Erlangen-Nürnberg, Erlangen, Germany

<sup>7</sup> Department of Internal Medicine, School for Cardiovascular Diseases CARIM; Maastricht University Medical Center+, Maastricht, The Netherlands

<sup>8</sup> VAS – European Independent Foundation in Angiology/Vascular Medicine – Microcirculation Working Group

**Summary:** The term “microcirculation” refers to the terminal vascular network of the body, which includes arterioles, capillaries, venules as well as initial lymphatic vessels. Additionally, it insinuates to their unique function in thermoregulation, fluid balance, maintenance of cellular exchange, and metabolism. Disturbances of microvascular function were identified to precede macrovascular involvement in the presence of cardiovascular risk factors and is the hallmark of terminal disease stages like critical limb or acral ischemia. Nevertheless, despite its obvious significance in vascular medicine assessment of microvascular function became increasingly neglected in the clinical institutions during the last decades and seems to play a subordinary role in medical education. We therefore provide an overview over relevant and clinically practicable methods to assess microcirculation in vascular medicine with critical estimations of their pros and cons and their perspectives in the future.

**Keywords:** Capillary microscopy, laser speckled contrast analyzer, O2C, tcpO2, indocyanine green fluorescence angiography

## Introduction

Apparative, ultrasound-based, and radiologic methods support physicians to diagnose and stage vascular diseases [1–4]. In the past decades, pressure and ultrasound-based tools like ABI measurement dominated the primary diagnostic armamentarium of angiologists due to their non-invasiveness, delegability, and easy handling [5, 6], although there is clear evidence now that it is the microvascular function that is altered first in the presence of cardiovascular risk factors associated with atherosclerosis and that it is the condition of the microcirculation (and not pressure values) that determines prognosis in critical disease stages [7–11].

Nevertheless, assessment of microvascular function has become almost an orphan art in angiology reduced to measurement of transcutaneous oxygen pressure in critical limb ischemia or diabetic foot syndrome and capillary microscopy in Raynaud’s phenomenon, at best.

During the 2018 VAS European Vascular Days in Milano, Italy, an international VAS Microcirculatory Group of experts in this field was founded to re-sensitize vascular physicians for microcirculatory issues in clinical institutions, research, and education.

The following paper provides an overview over clinically relevant and practicable methods to assess microcirculation in clinical settings.

## Methods of microvascular assessment

### Capillary microscopy

Videocapillaroscopy (VCM) is a simple, non-invasive, and relatively inexpensive imaging technique that allows in vivo morphological assessment of capillaries and evaluation of nutritional blood flow [12, 13]. It is usually performed in the nailfolds of the fingers but might also be applied at the nailfolds of the toes, the conjunctivae, the buccal mucosa, or the skin surface [12–14].

### Technical aspects

The best magnification to evaluate nailfold capillaries in detail is  $\geq 200 \times$ . Lower magnifications (80–100  $\times$ ) are used for overview-images of the architecture of the capillary bed and assessment of capillary density, which varies

from 7–12 capillaries per mm in nailfolds of the fingers and toes in the first row to about 30 per mm on the dorsal surface of the forefoot, up to 70 per mm on the skin of the fingers and toes in healthy subjects [12–15].

VCM is obtained by pilling the tube of a conventional microscopy to a HD-videocamera connected to a computer system, which runs an imaging and analyzing software or by using a contact-probe equipped with 100 × and 200 × contact lenses connected to a computer with comparable software. Hand-held devices with USB-computer connections or blue-tooth connections to iPhones or iPods are also available, but often lack official certification for medical use.

### Preliminaries

The patients should rest in a calm room with ambient temperature (20–23 °C) for a minimum of 15 minutes before starting the examination.

### Methodology

Skin capillaries are usually arranged vertically to the skin surface, but in the nailfolds the capillaries are oriented horizontally. Therefore, only the apex of the capillary loops can be visualized in the skin, while in the nailfolds the afferent loop, the apex region, and the efferent loop of the capillaries as well as the venules are visualized [12–16].

In the skin, there are usually 1–3 capillary loops in each papilla. The tip of the capillaries is often seen as a dot or comma shaped structure [13, 14]. Atypical capillary formations like branching, bleedings, and reductions in capillary density are pathologic findings [13, 14]. In the nailfolds, the following morphologic and functional parameters are assessed: visibility, architecture, capillary density, morphology, diameter, and length of the capillary loops, extracapillary findings like bleedings, and capillary flow characteristics [12–16]. Normal capillaries in the nailfolds are hairpin shaped or tortuous, while a reduced density, bleedings, elongated, branched or dilated capillaries must be considered as single pathologic findings, that might also be seen occasionally in healthy volunteers [12, 14, 17, 18]. This underlines the necessity to assess and classify the whole capillary pattern in order to avoid false positive diagnostic results [12, 14, 18, 19]. Dilated capillaries > 50 µm in the apex region are referred to as “megacapillaries” and are not found in healthy individuals but are an important aspect of scleroderma pattern [12, 17, 18, 19–23].

Nailfold video-capillaroscopy (NVC) should best be performed in the fingers D 2–5 [12, 15, 16]. As the thumb and the index finger often exhibits significant hornification they might not be examined without any significant loss of information [12]. The best visibility is generally found in the 4<sup>th</sup> and 5<sup>th</sup> fingers of the non-dominant hand, where the skin shows a greater degree of transparency than in the dominant hand as well as in white collar works compared to mechanists [12]. The patient usually sits in an upright position in front of the capillaroscope resting the palm of the hand on its observation surface. Pressure on the skin or nails should be avoided, especially when

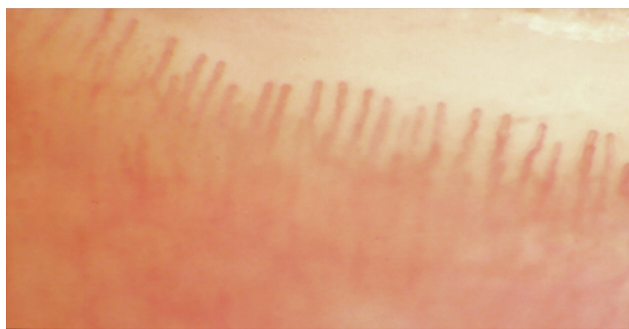
hand-held devices are used. With these devices the examination can also be performed in a supine position without further technical support, while a pivot arm is necessary for examinations in a supine position using a tube-microscope. To increase transparency, a drop of oil is placed on the nailfold bed of each finger or the skin region of interest. Fingers formerly affected by trauma or scarred regions of the skin should be excluded from analysis.

### Clinical applications

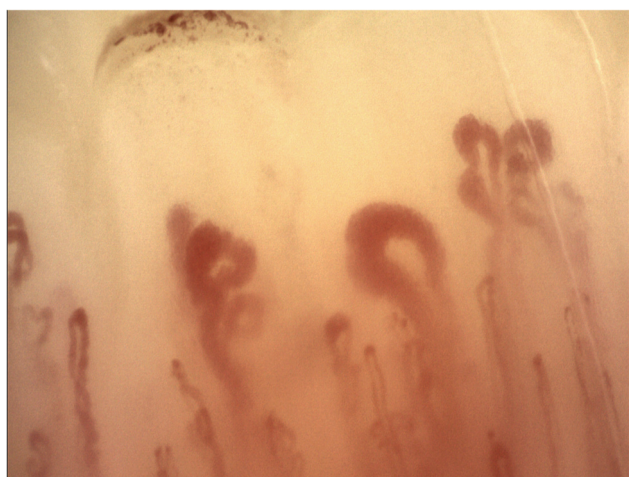
While angiologists were once leading in this field during the last decades NVC has found much more attention amongst rheumatologists. Many new findings and re-definitions were published especially in patients with connective tissue disorders [12, 20–29]. VCM was promoted as a first line diagnostic tool in Raynaud’s phenomenon and in suspected connective tissue diseases, especially systemic sclerosis [12, 30, 31]. It proved helpful to differentiate between a normal capillary pattern (see Figure 1), which is easy to learn and reproduce, unspecific morphologic or functional changes, and specific capillaroscopic pattern associated with scleroderma spectrum disorders [12, 32–34].

The best described pathologic pattern in VCM is the “scleroderma pattern” (SP) found in systemic sclerosis (SSc) and associated connective tissue diseases. The SP is characterized by a disturbance of the capillary architecture, a diminished capillary density, the presence of enlarged capillaries and megacapillaries (giant capillaries), hemorrhages, and neo-angiogenesis [19, 20, 23]. In 1983, Maricq and Le Roy first described two main types of capillaroscopic patterns in scleroderma with prognostic implications. The “slow pattern”, which was characterized by ectatic capillaries and the absence of extensive avascular areas, was associated with a less severe disease manifestation, while the “active pattern” characterized by an extensive loss of capillaries and advanced architectural de-arrangement associated with more severe disease [35]. Cutolo et al. re-defined scleroderma pattern in early, active, and late pattern [20–23]. Figure 2 describes an example of an active pattern. Similar morphologic changes can be found in patients with dermatomyositis as well as in yet undifferentiated connective tissue disease, referred to as “scleroderma like pattern”, while systemic lupus erythematoses is not characterized by a pathognomonic capillary morphologic pattern [12, 24, 25, 28, 36, 37]. If antiphospholipid syndrome is present, it might be characterized by hemosiderin deposits arranged linearly around the capillary loops caused by microbleedings and/or blunt capillary thrombosis [38–40].

The risk of developing a digital ulcer in scleroderma patients is highly defined by the capillary density: The lower the density, the higher the risk of developing a new ulcer and the lower the probability for ulcer healing. This correlation is the main basis for the CSURI, a capillary morphologic algorithm defined as  $DxM/N2$ , where M is the maximum diameter of the megacapillaries, M the number of the megacapillaries and N the number of capillaries. At least one megacapillary must be present in the image selected [41, 42].



**Figure 1.** Normal appearance and density of capillaries in the human nailfold. Notice normal density and regular appearance of the capillaries in the first row.



**Figure 2.** Scleroderma active pattern (according to Cutolo et al. [20–22]). Notice apex enlargement, megacapillaries, irregular capillary width, bleeding formation, and edema.

Essential acrocyanosis, another frequent functional vascular acrosyndrome, is characterized by the prevalence of sometimes markedly enlarged capillaries and elongated tortuous efferent loops. This pattern is usually homogeneously distributed in all fingers and might also involve the sub-papillary venules [43].

In peripheral and acral arterial occlusive disease progressive capillary morphologic abnormalities and a loss of density of acral skin capillaries have been described [13, 14, 44]. According to Fagrell's classification stage A is characterized by dilatations and apical micropools, stage B by hazy appearance, edema, and capillary hemorrhages, and stage C by a progressive reduction of capillary density up to a complete loss of capillaries [13, 14, 44]. Fagrell's stages were found to correlate well with limb prognosis and can thus be used to assess amputation threat in critical limb or acral ischemia [13, 14, 44]. Almost the same findings were described by others assessing chronic venous disease, especially in CEAP stages 5 and 6, where capillary density and morphologic alterations are associated with impaired wound healing and ulcer (re-)occurrence [45, 46].

Despite clear prognostic implications, the assessment of skin capillary morphology and density in critical limb or acral ischemia as well as in chronic venous disease did

not prevail in clinical routine – probably due to the fact, that high quality handheld capillary microscopy devices making such an examination much more easy and reliable were not available until recently and skin alterations, hornification, and edema are limiting factors.

There are unspecific capillaroscopic findings associated with a large spectrum of rheumatological and non-rheumatological diseases ranging from diabetes and hypertension to orphan diseases like Fabry's disease and rare inherited disorders. In this large spectrum of disorders, capillary microscopy might be useful to discover microvascular dysfunction and capillary damage, yet the prognostic or therapeutic implications of these findings often remain unclear [47].

### Future perspectives

The availability of hand-held capillary microscopes facilitates bed-site examinations or examinations in a supine patient's position. Thus, it is about time to re-evaluation the clinical usability and profit of VCM in critical limb or acral ischemia, and chronic venous disease with these new devices.

VCM might also become an important diagnostic tool for bed side assessment in critically ill patients. There is a growing number of studies being published in this area suggesting that the assessment of vascular density, blood flow heterogeneity, and – maybe most important – consequent early optimization of microcirculatory parameters may be associated with a better clinical outcome [48, 49].

There are first publications about automated analyzing software for VCM [48–50]. Artificial intelligence might thus be able not only to assist but also to automatically process and analyze capillary microscopy in the future [50–52].

### Limitations

VCM examines morphologic and functional aspects of capillaries and venules. Larger vessels or thermoregulative blood flow is not in the focus of this method. Up-stream pathologies should be assessed prior to VCM.

Nailfold capillary microscopy as well as skin capillaroscopy is limited by hornification. As in ischemic conditions the degree of hornification increases, capillary microscopy in this condition is also often hampered by reduced transparency of the skin. Same is true for craftsman.

Examination of colored people is hampered by the increased pigment content of the skin and might even be impossible.

Quantification of capillary flow or flow velocity is difficult due to its heterogeneity and the need of additional equipment and software.

### Laser speckled contrast analyzer

A laser Doppler is a non-invasive device to assess tissue microvascular perfusion. Depending on its penetration depth partial or total skin perfusion can be quantified



[53]. The technique is available in two different modes, the laser Doppler flowmetry and the laser Doppler imager resp. laser speckle contrast analyzer (LSCA) [54]. As Doppler flowmetry is nowadays mainly limited to scientific use only, we concentrate on LSCA in the description due to its wider use in clinical settings.

### Laser speckle contrast analyzer

The LSCA reveals spatial heterogeneity of tissue or wound perfusion without direct skin contact [53–55]. The skin area of interest is scanned by a laser-beam (in the Perimed PeriCam PSI system a 785 nm-laser-beam is used, which is invisible for humans). The backscattered light is analyzed by a CCD-camera-system rendering up to 100 pictures per second [56].

### Methodology

The technique is based on dynamic changes in the backscattered laser-light, which produces an interference pattern (speckle contrast pattern), that changes with changes in regional blood flow over time. Speckle contrast is defined as the ratio between the standard deviation of the intensity and the mean of the intensity. If there is high flow in the scanned tissue area, the standard deviation of the intensity will decrease and consequently the speckle contrast will decrease [54, 55]. The output signal is displayed in a color-coded image on a computer monitor: poor perfusion is usually expressed by blue, whereas higher perfusion is displayed by increasing quantiles of green, yellow and red [54–56]. A computer console is available for advanced analyses [56].

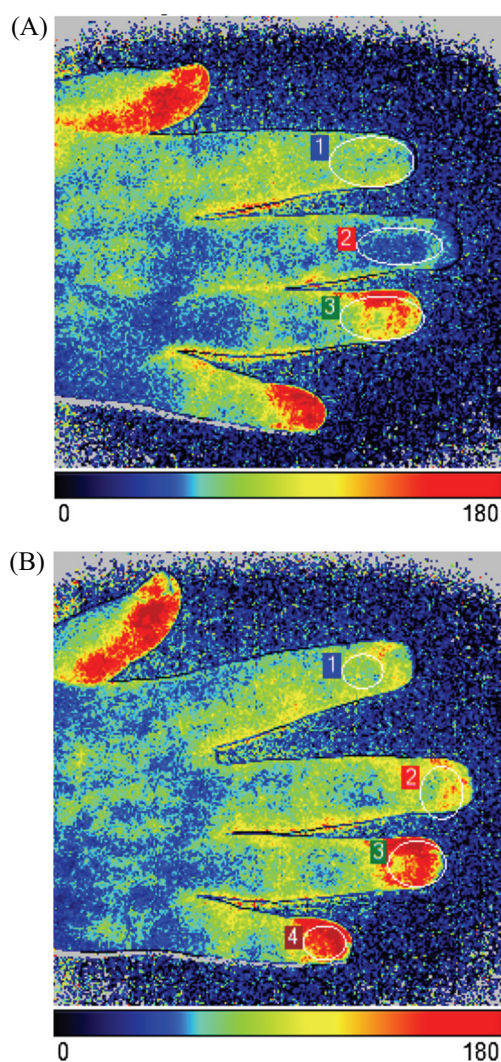
### Preliminaries

The patients should rest in a calm room with ambient temperature (20–23 °C) for a minimum of 15 minutes before starting the examination. Convection and temperature changes have to be avoided.

### Clinical applications

By means of this technique tissue perfusion in vascular acral syndromes and ulcers of various pathologies have been examined. Especially Cutolo and co-workers recently published a series of papers describing the usefulness of LSCA in the evaluation of Raynaud's phenomenon and scleroderma angiopathy [57–61].

According to these publications LSCA detected significant reductions of blood perfusion in areas usually affected by Raynaud's phenomenon (fingertips, periungual and palm areas), especially in patients with diffuse cutaneous systemic sclerosis. Perfusion values significantly correlated with the nailfold capillaroscopy scores of microangiopathy and showed progressive severity in early, active, or late stages [59]. Perfusion imaging with LSCA also correlated with skin dermal thickness at the level of dorsum of the middle phalanx of the third fingers in scleroderma patients [59]. LSCA also reliably monitored digital ulcer evolution and healing in systemic sclerosis, by evaluating areal skin



**Figure 3.** LSCA (Laser Speckle Contrast Analyzer)-Images. (A) Scleroderma digital ulcers II–III fingers. Notice malperfusion of the finger tips D III and III. (B) Same patient after Iloprost-infusions as well as nifedipine (long acting) and antiplatelet therapy p.o. Notice improved perfusion in the fingers, especially D II and III.

blood perfusion under standard treatment [61, 62]. An example is given in Figure 3.

The same group also published data about the inter-rater agreement and reliability of LSCA, which seemed to be good to excellent [62, 63].

In wounds, areas without granulation tissue usually shows low perfusion, while in granulation tissue perfusion is high indicating wound healing [64–66]. Scars usually show intermediary levels of perfusion. In intact skin adjacent to ischemic ulcers, perfusion is low reflecting overall ischemic conditions, while in chronic venous incompetence pathologic hyperperfusion of the skin or low perfusion (f.e. in atrophie blanche) might be found [67].

These findings led to the conclusion that wound healing is achieved by an increase of subpapillary perfusion in granulation tissue, while after formation of a scar it decreases to physiologic levels. In normal skin subpapillary perfusion is physiologically low, while in chronic venous incompetence it is often pathologically elevated due to hypertensive microangiopathy [64–67]. Additionally, an

increase of subpapillary perfusion was documented by laser Doppler imaging after the application of prostanoids [68].

Another clinical application of LSCA is burn-injuries, where laser Doppler systems assess burn depth with a good clinical correlation [69, 70].

### Future perspectives

The advantages of LSCA are the examination of relatively large skin area instead of a punctual measurement enabling the examiner to detect areal perfusion heterogeneities and the clearness of its documentation. LSCA is an easy to perform diagnostic tool with multiple clinical applications reaching from functional vascular acrosyndromes to critical limb ischemia, monitoring of wound-healing, monitoring of medical interventions, and pre- and postinterventional or operative controls.

### Limitations

The relatively small penetration depth only allows perfusion measurements of the upper skin areas. Stronger skin hornification, necrotic tissue, or scars limit its use. There are also motion artefacts in agitated patients or tremor, which might hamper or even preclude interpretation.

## O2C (Oxygen-to-see™; micro-lightguide spectrophotometry)

O2C is a diagnostic device for non-invasive assessment of blood flow, blood content and oxygen supply in soft tissues by use of glass fiber probes. The method is also referred to as spectrophotometry or micro-lightguide spectrophotometry in the literature.

### Technical aspects

A white light emitting probe also connected to a laser source radiates the skin and the underlying tissue. An integrated sensor detects the remitted light signals, while a computer determines doppler shifts by fast Fourier analysis. To determine the hemoglobin content and the oxygenated hemoglobin in the sample volume a wavelength range of 500–850 nm is used while flow is determined at 830 nm [3, 10].

O2C can be used as a single or multi-channel system with one channel recording the superficial tissue hemoglobin content and oxygen saturation of hemoglobin (e.g. of the skin), while a second channel monitors the oxygen supply and hemoglobin values of deeper tissues (e.g. subcutis, skeletal muscle) if a second probe with extended measurement volume is used. Maximal tissue penetration is about 2–3 cm.

- rHB reflects the hemoglobin amount in the tissue volume. As hemoglobin usually only circulates inside the (micro-)vessels this parameter reflects the filling of these vessels which itself depends on capillary density, capillary recruitment, and venous filling [3, 10]. The values are given in arbitrary units.
- SO<sub>2</sub> (ven). As more than two third of blood volume in the microcirculation is located in the venous pool with

this parameter mainly venolar oxygen saturation values are being measured. In contrast to the arterial oxygen saturation SO<sub>2</sub> (ven) reflects a balance between oxygen delivery and consumption. Low SO<sub>2</sub> ven-values indicate tissue hypoxia [3, 10]. Values are given in % of rHb.

- Flow is calculated by Doppler-shifts of emitted laser light induced by the movement of erythrocytes in the microcirculation [3, 10]. As the exact doppler angles in the tissue cannot be determined the values are given in arbitrary units.

All measurements can be performed easily by applying and fixing a small probe to the skin or wound surface with an adhesive film without pressure exertion and plugging in the connector. There is almost no time delay or equilibrium phase making measurements very fast and sensitive for chronologically or pharmacologically induced changes [3, 10]. Reproducibility is good, when comparable test conditions and exact repositioning are ensured.

### Preliminaries

As described above in other microcirculatory measurement systems the patient should relax under ambient temperature conditions (20–23 °C) for at least 15 min before measuring.

### Clinical applications

O2C was evaluated in critical limb ischemia, diabetic foot syndrome and for the prediction of early outcomes after balloon angioplasty and bypass surgery [71–73].

Maneuvers like elevation of extremities or measuring in dependent positions are valuable supplements, which increase diagnostic accuracy. For example, bringing the foot in an elevated position of 65 cm (corresponding to a hydrostatic pressure of 50 mmHg) is often used for the detection of critical limb or acral ischemia if flow decreases < 10 AU and SO<sub>2</sub> drops below 10% [3, 10]. On the other hand, venous insufficiency is characterized by a steep increase in rHb and a drop in SO<sub>2</sub> (ven) below 10% in depending position of the legs [3, 10]. O2C also helps to define the prognosis in wound healing if a wound mapping is performed and mean SO<sub>2</sub> (ven) is ≥ 30% and none of the SO<sub>2</sub>-values undercut 15% [3, 10]. As was already described above in the laser Doppler flowmetry-section provocation maneuvers like determination of post-occlusive reactive hyperemia, endothelial dependent and independent vasodilation, or reactions after oxygen insufflation or drug administration can also be performed with the O2C-device.

### Future perspectives

O2C meets many requirements for clinical use especially in critical acral or limb ischemia, diabetic foot syndrome, wound healing, and monitoring of therapeutic interventions. Advantageous is the short time requirement for the measurements and the combination of three parameters, which also allow conclusions on metabolic cell activity.

Combining this technology with high resolution ultrasound systems might be a wise further step to exactly

determine the tissue structures and to observe and measure regional tissue or organ perfusion in definite sectors.

### Limitations

O2C is a punctual measurement, reflecting only a small tissue volume. For areal perfusion analysis a mapping with consecutive multiple measurements is necessary.

Penetration depth cannot be determined exactly in tissues. There are only theoretical values. Thus, the exact anatomical point of measurement actually remains unclear.

## Transcutaneous oxygen tension (tcpO2)

Transcutaneous oxygen measurement is another non-invasive diagnostic method to analyze skin perfusion.

### Technical aspects

Historically, the method was significantly influenced by Clark et al. in 1953, who developed a special electrode with a heating element, an oxygen permeable membrane and a measurement chamber containing a microanode and -cathode [74]. This basic construction principle still operates in modern devices. Alternatively, a photo-optical measuring system that does not consume oxygen while measuring has been developed and successfully launched on the market [75].

Under hyperthermic conditions of the skin the surrounding O<sub>2</sub> partial pressure is lower than the underlying arterial oxygen pressure. This pressure gradient varies depending not only on the arterial oxygen pressure and the local air pressure, but also on the temperature, the tissue oxygen consumption, the tissue blood-flow, and capillary O<sub>2</sub>-shunting in the tissue [76]. Additional factors like the thickness of the epidermis, the degree of hornification, and contamination of the skin with ointments etc. also influence results. Heating a thermoelement over 43 °C induces local vasodilation underneath the probe, which is essential for facilitating O<sub>2</sub> diffusion, standardization, and reduction of intrinsic errors.

Using a Clark electrode-based system on the forefoot tcpO<sub>2</sub> values of 60–70 mmHg can be expected in a supine position [3]. On the other hand, values below 30 mmHg reflect critical limb ischemia by definition. Values below 10 have to be considered as being highly critical for the development of tissue necrosis respectively for non-healing of wounds and decubiti [3, 77–79]. The predictive value might be increased by performing provocation manoeuvres like measuring during leg dependency or oxygen inhalation [3, 77, 80].

Studies confirmed a hyperbole correlation between tcpO<sub>2</sub> and ankle-brachial index (ABI) [77]. TcpO<sub>2</sub> best reflects the degree of arterial perfusion deficit in the non-linear section of this hyperbolic function, i.e. at ABI values ≤ 0.5 [3, 77].

In the study by Urban et al. the absolute difference between the Radiometer TINA device and the Medicap device was approximately 15 mmHg in favor of the Medicap system [81]. Thus, tcpO<sub>2</sub> values can not be

compared directly between both methods, which indeed are based on different physiologic phenomena. Comparing regional perfusion indices (RPI, see below) might help to overcome these difficulties.

To increase validity, indices between different measuring points or additional provocation maneuvers were proposed:

1. Regional perfusion index is used to eliminate cardio-respiratory influences and simplify interpretation [80]. The reference electrode is placed on the chest.

$$RPI = \frac{tcpO_2 \text{ limb}}{tcpO_2 \text{ chest}}$$

Quotients of < 0.4 predict poor limb-associated outcome due to critical ischemia, while indices > 0.6 are usually associated with good limb associated prognosis and wound healing [82].

2. Measuring exercise transcutaneous oxygen pressures under standardized conditions, f.e. treadmill testing. This method has been used to confirm peripheral arterial disease in volunteers. A drop of 15 mmHg in the tcpO<sub>2</sub> from baseline values while walking was determined to represent a pathologic test result [81, 83].
3. Repetitive measurement in a depending limb position increases sensitivity of critical limb ischemia when an adequate increase in tcpO<sub>2</sub> is absent. The increase in depending position is called “microcirculatory reserve function” (MCR). MCR was shown to predict response to therapeutic interventions and limb outcome [78].  
F.e., in spinal cord stimulation MCR (tcpO<sub>2</sub> in depending position – tcpO<sub>2</sub> in supine position) > 17 mmHg predicts good response to the procedure, while values < 17 mmHg predict poor limb outcome even in case of stimulation [84].
4. An increase in tcpO<sub>2</sub> under oxygen inhalation is also considered to be a sensitive measure of the degree and compensation of critical limb ischemia [80].

### Preliminaries

For valid tcpO<sub>2</sub> measurements the patient should be placed in a supine position and remain in a stable ambient temperature of 21–23 °C after relaxing for at least 15 min. Smoking and coffee intake should be prohibited prior to the measurement. Clark electrodes have to be calibrated to local air pressure conditions prior to the measurement, while the photo-optical system has an automatic calibration function.

The skin under the probes should be prepared by removing hornification and cleaned with alcohol. Electrodes should be placed carefully at sites without scars, hairs, or skin defects as well as apart of skin veins. To avoid leaking adhesive pads are used for proper fixation.

### Clinical applications

TcpO<sub>2</sub> measurement is used in low ABI values to improve prognostic accuracy and to predict wound or amputation healing.



TcpO<sub>2</sub> predicts short term outcome after below the knee angioplasty in critical limb ischemia [85] and wound healing in limb ischemia and in chronic venous incompetence [78, 79]. TcpO<sub>2</sub> has also been shown to predict amputation high in non-reconstructible peripheral arterial occlusive disease [86]. For this purpose, multiple measurements preferably with multichannel systems in different regions of the foot or lower limb are necessary (mapping, determination of isobares). Values < 10 mmHg in a supine position strongly argue against stump healing, while a cut-off value of 20 mmHg had a negative predictive value of about 50% [3]. Nevertheless, there are limitations like the presence of skin edema, local infections, scarring or thickening of the skin that do not allow accurate measurements. Furthermore, one has to bear in mind that tcpO<sub>2</sub> only reflects skin perfusion, not perfusion of deeper soft tissue structures like calf muscles.

### Future perspectives

TcpO<sub>2</sub> is already well implemented in vascular medicine and there is a relatively wide distribution and a high level of experience with this method. Implementation of new provocation tests could extend effectivity and validity especially in the early stages f.e. of diabetic angiopathy where the sensitivity and specificity of standard tests like ABI is relatively low.

### Limitations

TcpO<sub>2</sub>-measurement with a Clark electrode is time consuming. Standard Clark electrodes need about 15–20 min to assure steady state measuring conditions. With the Medicap system time loss is much lower, which results in a high economic advantage in clinical routine, but both methods are not comparable by numbers, but at best by calculations of regional perfusion indices (RPI). Thus, all absolute values published for Clark electrode (f.e. 30 mmHg in the actual definition of critical limb ischemia) measurements must not be transferred for measurements with a photo-optical system.

TcpO<sub>2</sub> measurement is used in low ABI values to improve prognostic accuracy and to predict wound or amputation healing. Nevertheless, there are limitations like the presence of skin edema, local infections, scarring or thickening of the skin that do not allow accurate measurements. TcpO<sub>2</sub> reflects skin perfusion only, not perfusion of deeper soft tissue structures.

## Indocyanine green fluorescence angiography

Fluorescence angiography represents an imaging method that uses the optical phenomenon of fluorescence. The technique itself is well known and has been applied for various indications as the assessment of microvascular perfusion especially in ophthalmology. More recently, the fluorescence angiography is getting more and more important with regard to wound healing and perfusion

assessment in CLI patients as well as in reconstructive surgery.

### Technical aspects

The optical phenomenon of fluorescence is induced by electromagnetic radiation that is absorbed by fluorochrome substances in tissue that are thereby excited. These substances are visualized as excitation leads to emission of light. Particular substances carry an auto-fluorescence effect after irritation using specific wavelengths [87]. However, in vascular medicine a fluorochrome that increases contrast is of major relevance. Therefore, Indocyanine green (ICG) is widely used for vascular indications [88].

ICG is a water-soluble fluorochrome, which needs to be infused intravenously. ICG is transported in blood linked to plasma proteins and metabolized by the hepatobiliary system. Due to its properties, it can be used safely in patients with chronic kidney failure, which represents a relevant advantage in CLI patients. Iodine allergy poses a contraindication for ICG, though rates of further adverse reactions is very low (4:240.000) [89].

After intravenous application of the fluorescence dye, the ICG is excited by a near infrared light source and the tissue perfusion can thereby be visualized up to a depth of 5–7 mm. The absorption peak of ICG is at 800–810 nm, the emission peak at 830 nm [90].

There are several fluorescence angiography systems for the assessment of tissue perfusion commercially available.

An interpretation and quantification of the video sequences can be achieved on base of a grey scale. The different fluorescence intensities are encoded in a 256 grey scale matrix. Different fluorescence systems are available with already integrated analysis software and tools. Based on a grey scale score, the video sequences are analyzed. Different relative parameters are defined for quantification, such as Ingress (IN, difference of the maximum – minimum intensity in each sequence) and the Ingressrate (InR, increase of fluorescence intensity per second). Other analysis tools aim to quantify the time to accumulation (time to slope, i.e. the time from ICG application to first detection in tissue).

### Preliminaries

Measurements should be performed in a stable ambient temperature of 21–23 °C after relaxing for at least 15 min. As an intravenous application of ICG is necessary and allergic reactions have been reported, written consent should be secured.

### Clinical applications

The first clinical trials with ICG in humans were performed in 1957 at the Mayo Clinic, the US Food and Drug Administration approved the method already in 1959 [91]. Initially, fluorescence angiography was clinically used in intensive care medicine for measurement of the liver function by the so called ICG clearance test [91]. In the field of cardiology, ICG was then used to monitor cardiac

output and to visualize outflow of single cardiac bypasses intraoperatively [92]. Its most widespread application is nowadays in ophthalmology, where fluorescence angiography was implemented in the 1970s to visualize retinal perfusion [93]. In recent years, ICG found wide acceptance in the fields of plastic and reconstructive surgery to monitor free tissue transplantations, as well as in the field of vascular and transplantation surgery [94–102].

A significant advantage of the ICG angiography is its relatively simple intraoperative application compared to other angiography methods (x-ray, CTA, MRA). Intraoperatively, ICG can be used for direct visualization of the bypass graft and the anastomosis for patency control. Another application is the assessment of tissue perfusion on the level of microcirculation. This aspect is of special interest in patients suffering from chronic critical limb ischemia (CLI) [99, 101].

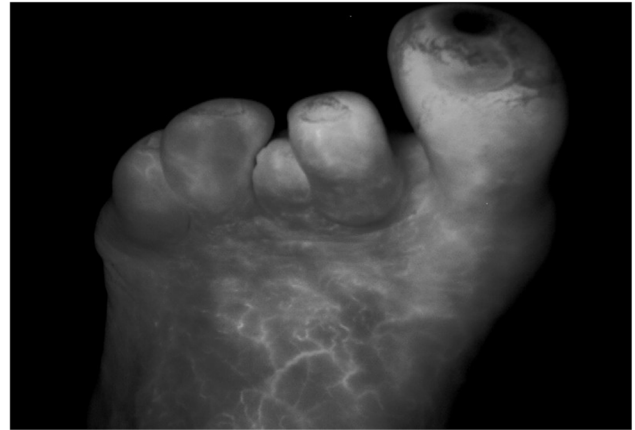Several studies have been performed to implement the fluorescence angiography technique in vascular procedures [96, 98, 100, 101]. After tibial bypass surgery this method can be used to detect an improvement of the foot microcirculation, that additionally correlates with the macrocirculation (ankle-brachial-index) [101]. The reproducibility has been tested and revealed a high level of concordance in sequential measurements [100]. Significant correlation to other methods of perfusion analysis such as tcpO<sub>2</sub> has been shown as well [100].

Compared to other perfusion assessments, the advantage of the fluorescence angiography investigation is the visualization of tissue perfusion. This gives the investigator an immediate impression of the foot's regional perfusion or perfusion deficits. An example is given in Figure 4. On base of these findings, minor amputation procedures can be planned, and the perfusion of wound beds can be investigated.

Another interesting application of ICG fluorescence angiography is its use in kidney transplantation surgery [94, 95, 102, 103]. As common digital subtraction angiography is not applicable due to its potential nephrotoxic effects, there is a need of an alternative intraoperative quality control. ICG fluorescence angiography represents a new alternative option, that has recently been established. In addition to the visual intraoperative organ perfusion control, the fluorescence parameters Ingress and Ingressrate have been established for quantification. These two parameters can predict an impaired organ function at the time of transplantation, as pre-existing chronic morphological changes in the kidney biopsy specimens lead to significant reduced perfusion parameters intraoperatively [102].

### Future perspective

As there are multiple areas of application and the use is relatively simple, fluorescence angiography may gain more impact in the future for the investigation of skin or organ microcirculation. Further studies might focus on the inter-individual comparability of the fluorescence parameters



**Figure 4.** ICG fluorescence angiography of the forefoot. Notice ulceration and severe malperfusion of the first toe of the left foot in critical limb ischemia.

and to establish cut off values, which can for example predict clinical endpoints like wound healing.

### Limitations

One main limitation of this method is its application in infected areas. In these patients, the perfusion analysis yields hyperperfusion that is incoherent with the real perfusion due to a reactive hyperaemia based on the infection.

While the dye is relatively inexpensive, the costs of the equipment is still very high. Additionally, potential allergic reactions have to be taken into account.

## Discussion

Marcello Malpighi in 1661 first discovered tiny vessels linking the arterial and venous system and thus introduced the concept of microcirculation [104]. Soon after his observation Antoni van Leeuwenhoek described the movement of blood cells in frog capillaries with a self-made microscope [105] and Johan Christophorus Kolhaus in 1663 noticed similar small vessels around the nails of humans [104], an observation that lay the foundation of modern nailfold capillaroscopy [106].

Since these early description's microcirculation gained variable attention by scientists and physicians over time. Periods of high appreciation and high scientific and technical output alternated with phases of negligence sometimes without plausible reasons.

Assessment of microcirculation became a cornerstone and a driving force in what could be retrospectively called “the golden age of angiology”, when the scientific and clinical fundamentals of the discipline were built (period between the 60<sup>th</sup> and 90<sup>th</sup> of the last century). What made angiologists successful at that time was a close connection between fundamental research especially in microcirculation and clinical research with high volume output and consecutively high scientific reputation of its representatives. In contrast, a significant output in microcirculation research from angiologists is nowadays lacking, while



rheumatologist discovered microcirculation as a new field of interest already dominating clinical publications in by far.

The reasons for this development might be numerous. First of all, the spread of ultrasonographic vascular diagnostics and developments in ultrasonographic devices with increasing resolution that have made the study of the macrocirculation much more easy, fascinating, and profitable for angiologists than sitting in front of a capillary microscopy or other time-consuming devices, which are poorly refunded or subsumed in an all-inclusive refunding system with obligatory duplex provision. Additionally, angiologists became increasingly engaged in vascular interventions in many countries, concentrating more on interventional techniques and progress in this field. Furthermore, in former times there were much more common scientific activities and meetings between vascular biologists and vascular clinicians, which led to synergistic effects and common scientific activities, while such points of contact and exchange are widely missing today.

In a long run this development might take revenge and uncouple angiologists from potentially rewarding future developments in medicine as new devices for microvascular assessment appeal with rewarding perspectives by coupling morphologic and functional data on the vessel-cell and metabolic interface.

Already it became clear, that the development of cardiovascular complications in metabolic diseases like diabetes mellitus, obesity, hypertension, and hyperlipidemia is mainly driven by disturbances of microvascular disturbances which are already prevalent at time-points where macrovascular involvement is still absent [8, 9, 107–113].

This sequence opens new opportunities for an earlier identification of patients at risk and intensified primary prevention. The authors are also convinced, that on the other end of the spectrum clinically relevant therapeutic progress in yet deleterious conditions like non-reconstructible peripheral arterial or severe acral occlusive disease will only be possible by increasing the input in microcirculatory research, clinical microcirculatory assessment, and surveillance and solving problems in standardization, and definition of clear cut-off values.

The authors propose to reinforce knowledge and expertise in the field of microcirculation amongst vascular medical students and specialists and to upgrade microvascular assessment and disturbances in the curricula of vascular medical specialization in Europe.

As was shown in our overview, methods to assess different aspects of microvascular dysfunction have increased and already provide new and exciting fields of scientific and clinical applications inducing an urgent need for better standardization and clinical evaluation.

New developments coupling (micro-)imaging with functional data and artificial intelligence are under way, which will even expand our possibilities and the informational value and content of microcirculatory assessment in the future.

## References

1. Ma KF, Kleiss SF, Schuurmann RCL, Bokkers RPH, Ünlü Ç, De Vries JPM. A systematic review of diagnostic techniques to determine tissue perfusion in patients with peripheral arterial disease. *Expert Rev Med Devices*. 2019;16:697–710.
2. Mayr V, Hirschl M, Klein-Weigel P, Girardi L, Kundi M. A randomized cross-over trial in patients suspected of PAD on diagnostic accuracy of ankle-brachial index by Doppler-based versus four-point oscillometry based measurements. *Vasa*. 2019;48:516–22.
3. Kröger K, Gröchenig E (Hrsg.). Nicht invasive Diagnostik angiologischer Krankheitsbilder. 3. Auflage. ABW-Verlag, Berlin. 2017.
4. Lanzer P, Rösch J (ed.). *Vascular Diagnostics*. Springer-Verlag, Berlin Heidelberg. 1994.
5. Crawford F, Welch K, Andras A, Chappell FM. Ankle brachial index for the diagnosis of lower limb peripheral arterial disease. *Cochrane Database Syst Rev*. 2016;9:CD010680.
6. Tehan PE, Barwick AL, Sebastian M, Chuter VH. Diagnostic accuracy of resting systolic toe pressure for diagnosis of peripheral arterial disease in people with and without diabetes: a cross-sectional retrospective case-control study. *J Foot Ankle Res*. 2017;10:58.
7. Collins R, Cranny G, Burch J, Aguiar-Ibáñez R, Craig D, Wright K, et al. A systematic review of duplex ultrasound, magnetic resonance angiography, and computed tomography angiography for the diagnosis and assessment of symptomatic, lower limb peripheral arterial disease. *Health Technol Assess*. 2007;11(iii-iv, xi-xiii):1–184.
8. Sørensen BM, Houben AJHM, Berendschot TTJM, Schouten JSAG, Kroon AA, van der Kallen CJH, et al. Hyperglycemia is the main mediator of prediabetes- and type 2 diabetes-associated impairment of microvascular function: The Maastricht study. *Diabetes Care*. 2017;40:e103–e105.
9. Martens RJH, Houben AJHM, Kooman JP, Berendschot TTJM, Dagnelie PC, van der Kallen CJH, et al. Microvascular endothelial dysfunction is associated with albuminuria: the Maastricht Study. *J Hypertens*. 2018;36:1178–87.
10. Rother U, Lang W. Noninvasive measurements of tissue perfusion in critical limb ischemia. *Gefasschirurgie*. 2018;23 (Suppl 1):8–12.
11. Kluz J, Matecki R, Adamiec R. Practical importance and modern methods of the evaluation of skin microcirculation during chronic lower limb ischemia in patients with peripheral arterial occlusive disease and/or diabetes. *Int Angiol*. 2013;32:42–51.
12. Klein-Weigel PF, Sunderkötter C, Sander O. Nailfold capillaroscopy microscopy – an interdisciplinary appraisal. *Vasa*. 2016;45:353–64.
13. Bollinger A, Fagrell B. *Clinical Capillaroscopy. A guide to its use in clinical research and practice*. Hogrefe & Huber Publishers, Lewiston, N.Y. 1990.
14. Fagrell B. *Capillaroscopy*. In *VAS European book on angiology/vascular medicine*. 1st edition, Aracne editrice: Canterano; 2018. pp. 239–50.
15. Cutolo M, Pizzorni C, Sulli A. *Capillaroscopy*. *Best Pract Res Clin Rheumatol*. 2005;19:437–52.
16. Smith V, Pizzorni C. The videocapillaroscopic technique. In Cutolo M (ed.), *Atlas of capillaroscopy in rheumatic diseases*. Elsevier Srl, Milano. 2010.
17. Fahrig C, Heidrich H, Voigt B, Wnuk G. Capillary microscopy of the nailfold in healthy subjects. *Int J Microcirc Clin Exp*. 1995;15:287–92.
18. Hoerth C, Kundi M, Katzenschlager R, Hirschl M. Qualitative and quantitative assessment of nailfold capillaries by capillaroscopy in healthy volunteers. *Vasa*. 2012;41:19–26.
19. Maricq HR, LeRoy EC. Patterns of finger capillary abnormalities in connective tissue disease by “wide-field” microscopy. *Arthritis Rheum*. 1973;16:619–28.

20. Cutolo M, Sulli A, Pizzorni C, Accardo S. Nailfold Videocapillaroscopy assessment of microvascular damage in systemic sclerosis. *J Rheumatol.* 2000;27:155–60.
21. Cortes S, Cutolo M. Capillaroscopic patterns in rheumatic diseases. *Acta Reumatol Port.* 2007;32:29–36.
22. Cutolo M, Sulli A, Secchi ME, Olivieri M, Pizzorni C. The contribution of capillaroscopy to the differential diagnosis of connective autoimmune diseases. *Best Pract Res Clin Rheumatol.* 2007;21:1093–108.
23. Cutolo M, Matucci Cerinic M. Nailfold capillaroscopy and classification criteria for systemic sclerosis. *Clin Exp Rheumatol.* 2007;25:663–5.
24. Manfredi A, Sebastiani M, Campomori F, Pipitone N, Giuggioli D, Colaci M, et al. Nailfold videocapillaroscopy alterations in dermatomyositis and systemic sclerosis: Toward identification of a specific pattern. *J Rheumatol.* 2016;43:1575–80.
25. Lambova SN, Hermann W, Müller-Ladner U. Comparison of qualitative and quantitative analysis of capillaroscopic findings in patients with rheumatic diseases. *Rheumatol Int.* 2012;32:3729–35.
26. Smith V, Thevissen K, Trombetta AC, Pizzorni C, Ruaro B, Piette Y, et al. Nailfold capillaroscopy and clinical applications in systemic sclerosis. *Microcirculation.* 2016;23:364–72.
27. Pizzorni C, Sulli A, Paolino S, Ruaro B, Smith V, Trombetta AC, et al. Progression of organ involvement in systemic sclerosis patients with persistent “late” nailfold capillaroscopic pattern of microangiopathy: A prospective study. *J Rheumatol.* 2017;44:1941–2.
28. Cutolo M, Melsens K, Wijnant S, Ingegnoli F, Thevissen K, De Keyser F, et al. Nailfold capillaroscopy in systemic lupus erythematosus: A systematic review and critical appraisal. *Autoimmun Rev.* 2018;17:344–52.
29. Corominas H, Ortiz-Santamaría V, Castellví I, Moreno M, Morlà R, Clavaguera T, et al. Nailfold capillaroscopic findings in primary Sjögren’s syndrome with and without Raynaud’s phenomenon and/or positive anti-SSA/Ro and anti-SSB/La antibodies. *Rheumatol Int.* 2016;36:365–9.
30. Maricq HR, Weinberger AB, LeRoy EC. Early detection of scleroderma-spectrum disorders by in vivo capillary microscopy: a prospective study of patients with Raynaud’s phenomenon. *J Rheumatol.* 1982;9:289–91.
31. Ingegnoli F, Boracchi P, Gualtierotti R, Lubatti C, Meani L, Zahalkova L, et al. Prognostic model based on nailfold capillaroscopy for identifying Raynaud’s phenomenon patients at high risk for the development of a scleroderma spectrum disorder: PRINCE (prognostic index for nailfold capillaroscopic examination). *Arthritis Rheum.* 2008;58:2174–82.
32. Pavlov-Dolijanovic S, Damjanov NS, Stojanovic RM, Vujasinovic Stupar NZ, Stanisavljevic DM. Scleroderma pattern of nailfold capillary changes as predictive value for the development of a connective tissue disease: a follow-up study of 3,029 patients with primary Raynaud’s phenomenon. *Rheumatol Int.* 2012;32:3039–45.
33. Rodriguez-Reyna TS, Bertolazzi C, Vargas-Guerrero A, Gutiérrez M, Hernández-Molina G, Audisio M, et al. Can nailfold videocapillaroscopy images be interpreted reliably by different observers? Results of an inter-reader and intra-reader exercise among rheumatologists with different experience in this field. *Clin Rheumatol.* 2019;38:205–10.
34. Cutolo M, Melsens K, Herrick AL, Foeldvari I, Deschepper E, De Keyser F, et al. Reliability of simple capillaroscopic definitions in describing capillary morphology in rheumatic diseases. *Rheumatology (Oxford).* 2018;57:757–9.
35. Maricq HR, LeRoy EC, D’Angelo WA, Medsger TA Jr., Rodnan GP, Sharp GC, et al. Diagnostic potential of in vivo capillary microscopy in scleroderma and related disorders. *Arthritis Rheumat.* 1980;23:183–9.
36. Marcoccia A, Rossi M. Raynaud Related Diseases. In *VAS European book on angiology/vascular medicine.* 1st edition, Aracne editrice, Canterano; 2018. pp. 907–16
37. Cutolo M, Melsens K, Wijnant S, Ingegnoli F, Thevissen K, De Keyser F, et al. Nailfold capillaroscopy in systemic lupus erythematosus: A systematic review and critical appraisal. *Autoimmun Rev.* 2018;17:344–52.
38. Candela M, Pansoni A, De Carolis ST, Pomponio G, Corvetta A, Gabrielli A, et al. Nailfold capillary microscopy in patients with antiphospholipid syndrome. *Recenti Prog Med.* 1998;89:444–9.
39. Sander O, Sunderkötter C, Kötter I, Wagner I, Becker M, Herrgott I, et al. Capillaroscopy. Procedure and nomenclature. *Z Rheumatol.* 2010;69:253–62.
40. Aslanidis S, Pырpasopoulou A, Doumas M, Triantafyllou A, Chatzimichailidou S, Zamboulis C. Association of capillaroscopic microhaemorrhages with clinical and immunological antiphospholipid syndrome. *Clin Exp Rheumatol.* 2011;29:307–9.
41. Sebastiani M, Manfredi A, Colaci M, D’Àmico R, Malagoli V, Giuggioli D, et al. Capillaroscopic Skin Ulcer Risk Index: A new prognostic tool for digital skin ulcer development in systemic sclerosis patients. *Arthritis & Rheumatism (Arthritis Care & Research).* 2009;61:688–94.
42. Sebastiani M, Manfredi A, Vukatana G, Moscatelli S, Riato L, Bocci M, et al. Predictive role of capillaroscopic skin ulcer risk index in systemic sclerosis: a multicentre validation study. *Ann Rheum Dis.* 2012;71:67–70.
43. Monticone G, Colonna L, Palermi G, Bono R, Puddu P. Quantitative nailfold capillary microscopy findings in patients with acrocyanosis compared with patients having systemic sclerosis and control subjects. *J Am Acad Dermatol.* 2000;42:787–90.
44. Fagrell B, Lundberg G. A simplified evaluation of vital capillary microscopy for predicting skin viability in patients with severe arterial insufficiency. *Clin Physiol.* 1984;4:403–11.
45. Steins A, Hahn M, Jünger M. Venous leg ulcers and microcirculation. *Clin Hemorheol Microcirc.* 2001;24:147–53.
46. Jünger M, Steins A, Hahn M, Häfner HM. Microcirculatory dysfunction in chronic venous insufficiency (CVI). *Microcirculation.* 2000;7:S3–12.
47. Jammal M, Kettaneh A, Cabane J, Tiev K, Toledano C. Periungueal capillaroscopy: an easy and reliable method to evaluate all microcirculation diseases. *Rev Med Interne.* 2015;36:603–12.
48. do Amaral Tafner PF, et al. Recent advances in bedside microcirculation assessment in critically ill patients. *Rev Bras Ter Intensiva.* 2017;29:238–247.
49. Scorcella C, Damiani E, Domizi R, Pierantozzi S, Tondi S, Carsetti A, et al. MicroDAIMON study: Microcirculatory DAILY MONitoring in critically ill patients: a prospective observational study. *Ann Intens Care.* 2018;8:64.
50. Hilty MP, Guerci P, Ince Y, Toraman F, Ince C. MicroTools enables automated quantification of capillary density and red blood cell velocity in handheld vital microscopy. *Commun Biol.* 2019;2:217.
51. Clendenon SG, Fu X, Von Hoene RA, Clendenon JL, Sluka JP, Winfree S, et al. A simple automated method for continuous fieldwise measurement of microvascular hemodynamics. *Microvasc Res.* 2019;123:7–13.
52. Cheng C, Lee CW, Daskalakis C. A reproducible computerized method for quantitation of capillary density using nailfold capillaroscopy. *J Vis Exp.* 2015:e53088.
53. Martini R, Abraham P., *Laser Doppler fluxmetry.* In *VAS European Book on Angiology/Vascular Medicine.* 1st edition. Aracne editrice, Canterano, pp. 251–5.
54. Wardell K, Jakobsson A, Nilsson GE. Laser Doppler perfusion imaging by dynamic light scattering. *IEEE Trans Biomed Eng.* 1993;40:309–16.
55. Fredriksson I, Larsson M. On the equivalence and differences between laser Doppler flowmetry and laser speckle contrast analysis. *J Biomed Opt.* 2016;21(12):126018.
56. Briers JD, Webster S, Laser speckle contrast analysis (LASCA): a non-scanning, full-field technique for monitoring capillary blood flow. *J Biomed Opt.* 1996;1:174–9.
57. Ruaro B, Sulli A, Alessandri E, Pizzorni C, Ferrari G, Cutolo M. Laser speckle contrast analysis: a new method to evaluate peripheral blood perfusion in systemic sclerosis patients. *Ann Rheum Dis.* 2014;73:1181–5.

58. Sulli A, Ruaro B, Cutolo M. Evaluation of blood perfusion by laser speckle contrast analysis in different areas of hands and face in patients with systemic sclerosis. *Ann Rheum Dis.* 2014;73:2059–61.
59. Ruaro B, Sulli A, Pizzorni C, Paolino S, Smith V, Cutolo M. Correlations between skin blood perfusion values and nailfold capillaroscopy scores in systemic sclerosis patients. *Microvasc Res.* 2016;105:119–24.
60. Ruaro B, Paolino S, Pizzorni C, Cutolo M, Sulli A. Assessment of treatment effects on digital ulcer and blood perfusion by laser speckle contrast analysis in a patient affected by systemic sclerosis. *Reumatismo.* 2017;69:134–6.
61. Ruaro B, Sulli A, Smith V, Paolino S, Pizzorni C, Cutolo M. Short-term follow-up of digital ulcers by laser speckle contrast analysis in systemic sclerosis patients. *Microvasc Res.* 2015;101:82–5.
62. Cutolo M, Vanhaecke A, Ruaro B, Deschepper E, Ickinger C, Melsens K, et al. Is laser speckle contrast analysis (LASCA) the new kid on the block in systemic sclerosis? A systematic literature review and pilot study to evaluate reliability of LASCA to measure peripheral blood perfusion in scleroderma patients. *Autoimmun Rev.* 2018;17:775–80.
63. Lambrecht V, Cutolo M, De Keyser F, Decuman S, Ruaro B, Sulli A, et al. Reliability of the quantitative assessment of peripheral blood perfusion by laser speckle contrast analysis in a systemic sclerosis cohort. *Ann Rheum Dis.* 2016;75:1263–4.
64. Gschwandtner ME, Ambrozy E, Fasching S, Willfort A, Schneider B, Bohler K, et al. Microcirculation in venous ulcers and the surrounding skin: findings with capillary microscopy and a laser Doppler imager. *Eur J Clin Invest.* 1999;29:708–16.
65. Gschwandtner ME, Ambrozy E, Schneider B, Fasching S, Willfort A, Ehringer H. Laser Doppler imaging and capillary microscopy in ischemic ulcers. *Atherosclerosis.* 1999;142:225–32.
66. Gschwandtner ME, Ambrozy E, Maric S, Willfort A, Schneider B, Bohler K, et al. Microcirculation is similar in ischemic and venous ulcers. *Microvasc Res.* 2001;62:226–35.
67. Gschwandtner ME, Ehringer H. Microcirculation in chronic venous insufficiency. *Vasc Med.* 2001;6:169–79.
68. Gschwandtner ME, Koppensteiner R, Maca T, Minar E, Schneider B, Schnurer G, et al. Spontaneous laser Doppler flux distribution in ischemic ulcers and the effect of prostanoids: A crossover study comparing the acute action of prostaglandin E(1) and iloprost vs saline. *Microvasc Res.* 1996;51:29–38.
69. Hoeksema H, Van de Sijpe K, Tondou T, Hamdi M, Van LK, Blondeel P, et al. Accuracy of early burn depth assessment by laser Doppler imaging on different days post burn. *Burns.* 2009;35:36–45.
70. Ragol S, Remer I, Shoham Y, Hazan S, Willenz U, Sinelnikov I, et al. Static laser speckle contrast analysis for noninvasive burn diagnosis using a camera-phone imager. *J Biomed Opt.* 2015;20(8):86009.
71. Beckert S, Witte MB, Königsrainer A, Coerper S. The impact of the Micro-Lightguide O2C for the quantification of tissue ischemia in diabetic foot ulcers. *Diabetes Care.* 2004;27:2863–7.
72. Jørgensen LP, Schroeder TV. Micro-lightguide spectrophotometry for tissue perfusion in ischemic limbs. *J Vasc Surg.* 2012;56:746–52.
73. Weber K, Gebauer K, Lüders F, Meyborg M, Malyar N, Goerge T, et al. Micro-lightguide spectrophotometry (O2C<sup>®</sup>) as a predictor of intermediate outcome in patients with critical limb ischemia after percutaneous transluminal angioplasty (PTA). *Int Angiol.* 2014;33:518–2.
74. Clark LC Jr, Wolf R, Granger D, Taylor Z. Continuous recording of blood oxygen tensions by polarography. *J Appl Physiol.* 1953;6:189–93.
75. Whalen WJ, Riley J, Nair P. A microelectrode for measuring intracellular PO<sub>2</sub>. *J Appl Physiol.* 1967;23:798–801.
76. Sheffield PJ. Measuring tissue oxygen tension: a review. *Undersea Hyperb Med.* 1998;25:179–88.
77. Scheffler A, Rieger H. Clinical information content of transcutaneous oximetry (tcpO<sub>2</sub>) in peripheral arterial occlusive disease (a review of the methodological and clinical literature with a special reference to critical limb ischaemia). *Vasa.* 1992;21(2):111–26.
78. Wang Z, Hasan R, Firwana B, Elraiyah T, Tsapas A, Prokop L, et al. A systematic review and meta-analysis of tests to predict wound healing in diabetic foot. *J Vasc Surg.* 2016;63(2 Suppl):29S–36S.e1–2.
79. Brownrigg JR, Hinchliffe RJ, Apelqvist J, Boyko EJ, Fitridge R, Mills JL, et al. Performance of prognostic markers in the prediction of wound healing or amputation among patients with foot ulcers in diabetes: a systematic review. *Diabetes Metab Res Rev.* 2016;32(Suppl 1):128–35.
80. Scheffler A, Rieger H. A comparative analysis of transcutaneous oximetry (tcPO<sub>2</sub>) during oxygen inhalation and leg dependency in severe peripheral arterial occlusive disease. *J Vasc Surg.* 1992;16:218–24.
81. Urban M, Fouasson-Chailloux A, Signolet I, Colas Ribas C, Feuilloley M, Abraham P. Comparison of two devices for measuring exercise transcutaneous oxygen pressures in patients with claudication. *Vasa.* 2015;44(5):355–62.
82. Hauser CJ. Tissue salvage by mapping of skin surface transcutaneous oxygen tension index. *Arch Surg.* 1987;122:1128–30.
83. McDowell JW, Thiede WH. Usefulness of the transcutaneous pO<sub>2</sub> monitor during exercise testing in adults. *Chest.* 1980;78:853–5.
84. Ubbink DT, Gersbach PA, Berg P, Amann W, Gamain J. The best TcpO<sub>2</sub> parametersto predict the efficacy of spinal cord stimulation to improve limb salvage in patients with inoperable critical leg ischemia. *Int Angiol.* 2003;22:356–63.
85. Redlich U, Xiong YY, Pech M, Tautenhahn J, Halloul Z, Lobmann R, et al. Superiority of transcutaneous oxygen tension measurements in predicting limb salvage after below-the-knee angioplasty: a prospective trial in diabetic patients with critical limb ischemia. *Cardiovasc Intervent Radiol.* 2011;34:271–9.
86. Poredos P, Rakovec S, Guzic-Salobir B. Determination of amputation level in ischaemic limbs using tcPO<sub>2</sub> measurement. *Vasa.* 2005;34:108–12.
87. Nguyen QT, Tsien RY. Fluorescence-guided surgery with live molecular navigation – a new cutting edge. *Nat Rev Cancer.* 2013;13:653–62.
88. Alander JT, Kaartinen I, Laakso A, Pätälä T, Spillmann T, Tuchin VV, et al. A review of indocyanine green fluorescence imaging in surgery. *Int J Biomed Imaging.* 2012;2012:940585.
89. Marshall MV, Rasmussen JC, Tan IC, Aldrich MB, Adams KE, Wang X, et al. Near-infrared fluorescence imaging in humans with indocyanine green: A review and update. *Open Surg Oncol J.* 2010;2:12–25.
90. Fox IJ, Brooker LG, Haseltine DW, Essex HE, Wood EH. A tricarbo-cyanine dye for continuous recording of dilution curves in whole blood independent of variations in blood oxygen saturation. *Proc Staff Meet Mayo Clin.* 1957;32:478–84.
91. Leevy CM, Mendenhall CL, Lesko W, Howard MM. Estimation of hepatic blood flow with indocyanine green. *J Clin Invest.* 1962;41:1169–79.
92. Detter C, Wipper S, Russ D, Iffland A, Burdorf L, Thein E, et al. Fluorescent cardiac imaging: a novel intraoperative method for quantitative assessment of myocardial perfusion during graded coronary artery stenosis. *Circulation.* 2007;116:1007–14.
93. Flower RW. Injection technique for indocyanine green and sodium fluorescein dye angiography of the eye. *Invest Ophthalmol.* 1973;12:881–95.



94. Rother U, Amann K, Adler W, Nawroth N, Karampinis I, Keese M, et al. Quantitative assessment of microperfusion by indocyanine green angiography in kidney transplantation resembles chronic morphological changes in kidney specimens. *Microcirculation*. 2019;26:e12529.
95. Rother U, Gerken ALH, Karampinis I, Klumpp M, Regus S, Meyer A, et al. Dosing of indocyanine green for intraoperative laser fluorescence angiography in kidney transplantation. *Microcirculation*. 2017;24(8).
96. Rother U, Lang W, Horch RE, Ludolph I, Meyer A, Gefeller O, et al. Pilot assessment of the angiosome concept by intraoperative fluorescence angiography after tibial bypass surgery. *Eur J Vasc Endovasc Surg*. 2018;55:215–21.
97. Ludolph I, Arkudas A, Schmitz M, Boos AM, Taeger CD, Rother U, et al. Cracking the perfusion code? Laser-assisted Indocyanine Green angiography and combined laser Doppler spectrophotometry for intraoperative evaluation of tissue perfusion in autologous breast reconstruction with DIEP or ms-TRAM flaps. *J Plast Reconstr Aesthet Surg*. 2016;69:1382–8.
98. Settembre N, Kauhanen P, Albäck A, Spillerova K, Venermo M. Quality control of the foot revascularization using indocyanine green fluorescence imaging. *World J Surg*. 2017;41:1919–26.
99. Terasaki H, Inoue Y, Sugano N, Jibiki M, Kudo T, Lepántalo M, et al. A quantitative method for evaluating local perfusion using indocyanine green fluorescence imaging. *Ann Vasc Surg*. 2013;27:1154–61.
100. Venermo M, Settembre N, Albäck A, Vikatmaa P, Aho PS, Lepántalo M, et al. Pilot Assessment of the Repeatability of Indocyanine Green Fluorescence Imaging and Correlation with Traditional Foot Perfusion Assessments. *Eur J Vasc Endovasc Surg*. 2016;52:527–33.
101. Rother U, Lang W, Horch RE, Ludolph I, Meyer A, Regus S. Microcirculation evaluated by intraoperative fluorescence angiography after tibial bypass surgery. *Ann Vasc Surg*. 2017;40:190–7.
102. Hoffmann C, Compton F, Schäfer JH, Steiner U, Fuller TF, Schostak M, et al. Intraoperative assessment of kidney allograft perfusion by laser-assisted indocyanine green fluorescence videography. *Transplant Proc*. 2010;42:1526–30.
103. Sekijima M, Tojimbara T, Sato S, Nakamura M, Kawase T, Kai K, et al. An intraoperative fluorescent imaging system in organ transplantation. *Transplant Proc*. 2004;36:2188–90.
104. Ghosh SK, Kumar A. Marcello Malpighi (1628–1694): Pioneer of microscopic anatomy and exponent of the scientific revolution of the 17th century. *Eur J Anat*. 2018;22:433–9.
105. Tshisuaka Barbara I. Leeuwenhoek, Antony van. In . In WE Gerabek, BD Haage, G Keil, W Wegner (Hrsg.). *Enzyklopädie Medizingeschichte*. De Gruyter, Berlin/New York. 2005. S. 833.
106. Martinis MD, Ginaldi L. Capillaroscopy opens a window to look inside. *Rheumatology (Sunnyvale)*. 2014;4:e112.
107. Schlager O, Willfort-Ehringer A, Hammer A, Steiner S, Fritsch M, Giurgea A, et al. Microvascular function is impaired in children with morbid obesity. *Vasc Med*. 2011;16:97–102.
108. Schlager O, Hammer A, Willfort-Ehringer A, Fritsch M, Rami-Merhar B, Schober E, et al. Microvascular autoregulation in children and adolescents with type 1 diabetes mellitus. *Diabetologia*. 2012;55:1633–40.
109. Schlager O, Widhalm K, Hammer A, Giurgea A, Margeta C, Fritsch M, et al. Familial hypercholesterolemia affects microvascular autoregulation in children. *Metabolism*. 2013;62:820–7.
110. Houben AJHM, Martens RJH, Stehouwer CDA. Assessing Microvascular Function in Humans from a Chronic Disease Perspective. *J Am Soc Nephrol*. 2017;28:3461–72.
111. Sörensen BM, Houben AJ, Berendschot TT, Schouten JS, Kroon AA, van der Kallen CJ, et al. Prediabetes and type 2 diabetes are associated with generalized microvascular dysfunction: The Maastricht Study. *Circulation*. 2016;134:1339–52.
112. Jonk AM, Houben AJ, Schaper NC, de Leeuw PW, Serné EH, Smulders YM, et al. Obesity is associated with impaired endothelial function in the postprandial state. *Microvasc Res*. 2011;82:423–9.
113. Jonk AM, Houben AJ, Schaper NC, de Leeuw PW, Serné EH, Smulders YM, et al. Acute angiotensin II receptor blockade improves insulin-induced microvascular function in hypertensive individuals. *Microvasc Res*. 2011;82:77–83.

#### History

Submitted: 29.09.2019

Accepted after revision: 29.12.2019

Published online: 10.02.2020

#### Conflicts of interests

No conflicts of interest exist.

#### Correspondence address

Dr. med. Peter Franz Klein-Weigel, M.D.

Klinik für Angiologie

Ernst von Bergmann Klinikum

Charlottenstrasse 72

14467 Potsdam

Germany

p.klein-weigel@web.de